NEUROLOGIA I NEUROCHIRURGIA POLSKA XXX (2017) XXX–XXX

Available online at www.sciencedirect.com
ScienceDirect
journal homepage: http://www.elsevier.com/locate/pjnns

Original research article

Motor evoked potentials in patients with chronic whiplash-associated disorder grade II

Jacques De Reuck *

Department of Neurology, University Hospital, B-9000 Ghent, Belgium

ARTICLE INFO

Article history:
Received 20 March 2017
Accepted 30 June 2017
Available online xxx

Keywords:
Whiplash-associated disorders
Motor evoked potentials
Magnetic resonance imaging
Spinal cord injury
Outcome

ABSTRACT

Background and purpose: It is common belief that psychological problems influence the persistence of complains in patients with so-called mild whiplash-associated disorders (WADs). The usefulness of motor evoked potentials (MEPs) is investigated in patients with grade II WAD and remaining complains for more than 6 months.

Patients and methods: Twenty consecutive patients, aged between 24 and 58 years, with persistent neck pain for months after a car accident were included. All patients had a magnetic resonance imaging (MRI) of the cervical spine and cord. Central (CMCT) and peripheral motor conduction times (PMCT) were evaluated by registration in the biceps brachii muscle (C5–C6) and in the abductor digiti minimi muscle (C7–C8–Th1).

Results: Thirteen patients had prolonged CMCT or/and PMCT compared to 7 with normal values. On MRI discus bulging C5–C6, without abnormal signal changes in the cervical spinal cord was observed in 6 of the patients with disturbed MEPs compared to 3 without. Out of 7 patients, who had repeated MEPs after 6 months, 3 of them had an improvement of their conduction time. The patients with prolonged MEP conduction times were older than those with normal values ($p = 0.007$).

Conclusions: MEP examination has to be performed in all patients with persistent complains even in the absence of objective neurological signs and non-significant changes on imaging.

1. Introduction

The Quebec Task Force on whiplash-associated disorders (WAD) has classified patients as grade II when they have neck complains and musculoskeletal signs without objective neurological deficits [1]. However the prognostic implications of this classification remain controversial [2], particularly in patients with grade II [3]. Although the intensity of neck pain is a strong predictor of delayed recovery or permanent disability in WAD [4], the disorder is probably multi-factorial [5] and behavioural factors are important [6,7].

Magnetic resonance imaging (MRI) of the spine and cervical spinal cord does not contribute to explain the persistent complains after mild WAD [8–10]. Also most neurophysiologic examinations are not very helpful [11–15].

Motor-evoked potentials (MEPs) have already been used to evaluate cervical spinal cord disorders but no specific studies have been published in WAD [16,17].

* *Correspondence to*: Leopold II laan 96, BE-9000 Ghent, Belgium.
E-mail address: dereuck.j@gmail.com
http://dx.doi.org/10.1016/j.pjnns.2017.06.009
0028-3843/

Please cite this article in press as: De J. Motor evoked potentials in patients with chronic whiplash-associated disorder grade II. Neurol Neurochir Pol (2017), http://dx.doi.org/10.1016/j.pjnns.2017.06.009

It is common belief that psychological problems and pending litigation influence the persistence of complains in the absence of objective clinical findings in patients with so-called mild whiplash injury [18].

So there is a need to validate as much as possible objective findings that can explain the persistence of complains in patients with WAD.

The present study investigates the usefulness of MEPs, compared to other evoked potentials in a number of selected grade II WAD patients with remaining complains for more than 6 months.

2. Patients and methods

Twenty consecutive patients (7 males and 13 females), aged between 24 and 58 years, with persistent neck pain and headache for more than 6 months were included in this study. The complains were the consequence of an acceleration–deceleration mechanism of the neck during a motor vehicle collusion.

All the patients were seen between 6 months and 3 years after the car accident and after several unsuccessful treatment modalities. The neurological examination was normal in all of them. Neck mobilization was normal but painful.

All patients were submitted to a T1- and a T2-weighted MRI of the cervical spine and cord.

For the MEP examination of the brain and the cervical spinal cord a Cadwell circular coil was used [19]. MEPs were recorded during slight contraction at the level of the biceps brachii muscle (C5–C6) and of the abductor digiti minimi muscle (C7–C8–Th1) by stimulation of the contralateral motor cortex. Central motor conduction time (CMCT) was obtained by subtraction of the peripheral motor conduction time (PMCT). The latter was acquired by homolateral magnetic cervical root stimulation at the supraclavicular level. The intensity level of the current was set at 10–25% above the cortical excitation threshold determined at rest. The upper normal values under slight muscular contraction were those collected by the Dutch Neurophysiology Society (unpublished observations). Conduction times exceeding the average values plus the standard deviations (SD) of the PMCT and CMCT were considered as prolonged, indicating respectively radicular and pyramidal tract damage. The normal values were for PMCT 6.0 (SD: 0.5) ms and for CMCT 7.0 (SD: 1.5) ms on registration in the biceps brachii muscle. On registration in the abductor digiti minimi muscle the normal values for PMCT were 14.0 (SD: 1.0) ms and for CMCT 6.0 (SD: 2.0) ms.

In 7 patients the MEPs could be repeated 6 months after the first examination.

Brainstem auditory evoked potential (BAERs) and somatosensory evoked potentials (SSEPs), after electric stimulation of the median nerve with contralateral hemispheric registration were also performed in all patients.

When needed, univariate comparisons of unpaired groups were performed with the Fisher's exact test for categorical data and non-parametric Mann–Whitney *U*-test to compare continuous variables.

3. Results

Thirteen patients had prolonged CMCT or/and PMCT compared to 7 with normal values. The average time of the first MEP examination was 18 (SD: 14) months of the former compared 18 (SD: 12) months in the latter group. On the Universal Pain Assessment Scale the severity in both groups was similar between 6 (severe) and 8 (very severe). Six out of the 13 patients with disturbed MEPs, had prolonged SSEPs while BEARs were normal in all cases.

Discus bulging C5-CS, without abnormal signal changes in the cervical spinal cord was observed in 6 of the patients with disturbed MEPs compared to 2 without (Fig. 1).

Eleven patients had prolonged CMCTs at the level of C7–C8–Th1 with normal values at the level C5–C6. In 8 of them the prolonged CMCT was bilateral, while unilateral in 3 cases.

Four patients had prolonged PMCTs at the level of C5–C6 and one at the level of C7–C8–Th1. Three of them had also associated disturbed CMCTs at the level of C7–C8–Th1. In 3 out of the 5 patients the prolonged PMCTs were bilateral.

Out of the 7 patients, who had a repeated MEP examination after 6 months, 3 of them had an improvement of their conduction times.

The average age of the patients with prolonged MEP conduction times was 42 (SD: 9) years compared to 29 (SD: 6) years in the group with normal values ($p = 0.007$). The gender distribution was respectively 46% males in the former group compared to 29% in the latter ($p = 0.64$).

4. Discussion

The diagnosis of grade II WAD, defined as a simple ligament–muscular neck problem in patients with persistent complains, remains only valid after careful exclusion of spinal cord and root lesions [20]. The present study shows that a number of grade II WAD patients with persistent complains have indeed mild spinal cord and/or root lesions with a C5–C6 predilection level. Although MRI shows in a number of cases discrete discus

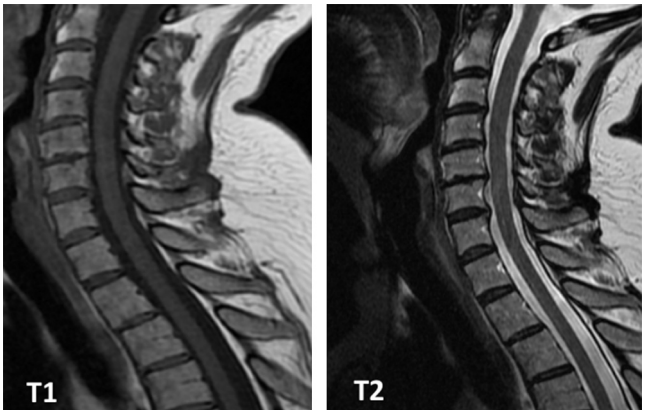

Fig. 1 – Sagital T1- and T2-weighted magnetic resonance imaging of a cervical spine and cord in a 53-year-old man with persistent neck complains 6 months after a grade II whiplash-associated disorder. Note the discrete discus bulging C5–C6 and the absence of spinal cord signals.

Please cite this article in press as: De J. Motor evoked potentials in patients with chronic whiplash-associated disorder grade II. Neurol Neurochir Pol (2017), http://dx.doi.org/10.1016/j.pjnns.2017.06.009