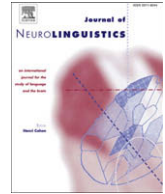




Contents lists available at ScienceDirect

Journal of Neurolinguistics

journal homepage: www.elsevier.com/locate/jneuroling



Early recovery from acquired child aphasia and changes of cerebral blood flow

Tomoyuki Kojima^{a,b,*}, Masaru Mimura^c, Kenichi Auchi^d, Masahiro Kato^e

^a Ichikawa Consultancy for Higher Brain Dysfunction, 4-4-5-703, Minami-Yawata, Ichikawa, Chiba 272-0023, Japan

^b Sendai Medical and Welfare Vocational College, Hokuto Educational Foundation, Japan

^c Department of Neuropsychiatry, Showa University School of Medicine, Japan

^d Department of Radiology, Tokyo Dental College, Ichikawa General Hospital, Japan

^e Department of Neurology, Edogawa Hospital, Japan

ARTICLE INFO

Article history:

Received 14 November 2008

Received in revised form 23 March 2009

Accepted 31 March 2009

Keywords:

Child aphasia

Recovery

Cerebral blood flow

Standard Language Test of Aphasia

ABSTRACT

Research into acquired child aphasia can provide useful evidence about the neural mechanisms involved in recovery from aphasia because the functional plasticity of the brain is greater in children than in adults. To investigate the neural correlates underlying functional recovery from acquired child aphasia, we followed a 9-year-old boy with aphasia for 2–16 months after traumatic head injury. The patient's language ability was assessed four times by the Standard Language Test of Aphasia (SLTA). Regional cerebral blood flow (rCBF) was also measured four times with ^{99m}Tc-ECD and a fully automated quantitative image analysis system. The patient showed substantial improvement of language during this period. Although overall rCBF fluctuated throughout the 1st–4th measurements, there was a significant relative dominance of rCBF in the left cerebral hemisphere compared with the right hemisphere throughout the four measurements, especially in the paracentral and temporo-parietal regions. These findings may suggest that the left cerebral hemisphere rather than the right hemisphere plays a major role in the early recovery from child aphasia.

© 2009 Elsevier Ltd. All rights reserved.

* Corresponding author. Ichikawa Consultancy for Higher Brain Dysfunction, 4-4-5-703, Minami-Yawata, Ichikawa, Chiba 272-0023, Japan. Tel./fax: +81 47 378 0781.

E-mail address: ihbd@w5.dion.ne.jp (T. Kojima).

1. Introduction

For clinicians involved in the management of aphasia, one of the most important issues is to investigate the underlying neural basis for the recovery of language ability. Recently, a number of functional neuroimaging studies documenting the recovery of acquired adult aphasia have been published (Calvert et al., 2000; Cao, Vikingstad, George, Johnson, & Welch, 1999; Heiss et al., 1997; Heiss, Kessler, Karbe, Fink, & Pawlik, 1993; Heiss, Kessler, Thiel, Ghaemi, & Karbe, 1999; Jodzio, Drumm, Nyka, Lass, & Gasecki, 2005; Karbe, Kessler, Herholz, Fink, & Heiss, 1995; Mimura et al., 1998; Rosen et al., 2000; Warburton, Price, Swinburn, & Wise, 1999; Winhuisen et al., 2005; Winhuisen et al., 2007).

However, the mechanisms of language reorganization during the course of the recovery from aphasia are still under debate. Heiss et al. (1993) investigated predictors of recovery from aphasia after ischemic stroke by positron emission tomography (PET) and their finding indicated the importance of left hemisphere integrity in the functional recovery of language. Karbe et al. (1995) also used PET and concluded that the cerebral metabolic rate of glucose in the left superior temporal cortex and pre-frontal cortex could predict the outcome of aphasia. Heiss et al. (1997) further suggested that good recovery from aphasia is related to partial sparing of the speech areas in the dominant hemisphere that can be (re-) activated, while predominant recruitment of contralateral areas failed to achieve marked recovery from aphasia. In a follow-up study of patients with aphasia due to stroke using repetitive transcranial magnetic stimulation (rTMS) and PET, Winhuisen et al. (2007) concluded that restoration of the left hemisphere network was more effective than that of the right hemisphere for recovery from aphasia.

On the other hand, there is some evidence favoring a right hemispheric mechanism. Heiss et al. (1999) performed a PET study and found that efficient restoration of language in aphasic patients is usually achieved if the left temporal area is preserved, but right hemispheric areas can contribute to language improvement if this region is destroyed. Calvert et al. (2000) performed an fMRI study, and concluded that recovery from dysphasia could be mediated by both the preservation of neuronal networks in and around the lesion and the recruitment of homologous regions in the contralateral hemisphere.

In children, it has been reported that the functional plasticity of the brain is greater than in adults and the outcome of acquired aphasia is thought to be better in children (Cranberg, Filley, Hart, & Alexander, 1987; Loonen & van Dongen, 1990; Martins & Ferro, 1991; Satz & Bullard-Bates, 1981). The child's immature brain has more strategies and capacity for recovery than the adult brain, and children have the potential to transfer language to either the right hemisphere or to functionally related but uncommitted areas of the left hemisphere, and such differences from adults are thought to be part of the explanation for the good prognosis of acquired child aphasia (Martins & Ferro, 1992). Lenneberg's (1967) equipotentiality hypothesis has been often quoted as accounting for better recovery from aphasia in children. According to this hypothesis, both hemispheres are equally able to sustain language function during the early years of life and lateralization to the left hemisphere develops progressively with brain maturation.

Regarding the critical age for language reorganization, Lenneberg (1967) noted that aphasia acquired before 10 years of age usually recovers completely, while post-pubertal focal brain lesions often result in permanent language deficits. However, recent studies have raised doubts about this critical period for recovery from acquired child aphasia, suggesting that it is less clear-cut than was indicated by Lenneberg. Woods and Teuber (1978) demonstrated that children who became aphasic after the age of 8 years still had symptoms more than 4 years later, whereas children who were younger than 8 at onset were no longer aphasic after the same time interval. In contrast, Cranberg et al. (1987) reported that all eight aphasic children whom they studied (four of them older than 8 years at onset) recovered within 5–10 months. Taking these findings into consideration, Martins (2004) proposed that the age of onset is not a significant prognostic factor.

Although we do not yet have sufficient evidence to understand the process of functional recovery from child aphasia, studies on the neural correlates of functional recovery from child aphasia may also contribute to better understanding of the recovery from adult aphasia.

In the present study, we followed a 9-year-old boy with acquired child aphasia due to traumatic brain injury (TBI) for 16 months after the onset. The patient underwent assessment of language and

متن کامل مقاله

دریافت فوری ←

ISIArticles

مرجع مقالات تخصصی ایران

- ✓ امکان دانلود نسخه تمام متن مقالات انگلیسی
- ✓ امکان دانلود نسخه ترجمه شده مقالات
- ✓ پذیرش سفارش ترجمه تخصصی
- ✓ امکان جستجو در آرشیو جامعی از صدها موضوع و هزاران مقاله
- ✓ امکان دانلود رایگان ۲ صفحه اول هر مقاله
- ✓ امکان پرداخت اینترنتی با کلیه کارت های عضو شتاب
- ✓ دانلود فوری مقاله پس از پرداخت آنلاین
- ✓ پشتیبانی کامل خرید با بهره مندی از سیستم هوشمند رهگیری سفارشات