

Distraction Lengthening Following Vascularized Second Toe Transfer for Isolated Middle Finger Reconstruction

Jiuzhou Lu, MD, PhD,* Youlai Zhang, MD,* Junjiang Jiang, MD, PhD,*
Lei Xu, MD, PhD,* Harvey Chim, MD†

Purpose We report the use of distraction lengthening of the middle phalanx after vascularized second toe transfer for middle finger reconstruction to lengthen the digit to match the index and ring fingers.

Methods We performed a retrospective review of 3 patients with a mean follow-up of 30 months.

Results A mean increase of 2.0 cm in the length in the digit was achieved. The range of motion at the proximal interphalangeal joint was preserved and bony union was seen at the distraction site in all 3 cases. All patients had an excellent functional and aesthetic outcome.

Conclusions Distraction lengthening of vascularized toe transfers is a feasible undertaking. (*J Hand Surg Am.* 2017;42(1):e33–e39. Copyright © 2017 by the American Society for Surgery of the Hand. All rights reserved.)

Type of study/level of evidence Therapeutic V.

Key words Toe to hand transfer, distraction osteogenesis, finger amputation, microsurgery, toe transfer.



ISOLATED LONG FINGER AMPUTATION AT the level of the proximal phalanx affects the grip strength of the hand and leaves a digit that does not have sufficient length to prevent objects from falling through the space between the index and ring fingers. Compared with the index, ring, and little fingers, the middle finger contributes the most to total grip strength.¹ An option for

treatment is ray amputation.² However, this decreases the span of the hand and results in decreased grip strength and tripod pinch.^{2,3} Another option is a finger prosthesis. Although this results in some improvement in hand function, the digits are difficult for some patients to learn to use and regular repair and maintenance are required, with prostheses having to be changed every 2 to 3 years.⁴ In many patients, the prostheses serve only a psychological role, with the benefit diminishing over time.⁴ In many patients, these 2 options may be sufficient.

Toe to hand transfer provides a functional and aesthetic reconstruction for isolated finger amputations. For more distal amputations at the level of the middle phalanx, distal interphalangeal joint, or distal phalanx, the missing part of the digit can be totally replaced by a toe.⁵

For more proximal amputations at the level of the proximal phalanx and more proximally, a toe to hand

From the *Department of Hand Surgery, Huashan Hospital, Fudan University, Shanghai, China; and the †Division of Plastic Surgery, University of Miami Miller School of Medicine, Miami, FL.

Received for publication March 21, 2016; accepted in revised form November 4, 2016.

No benefits in any form have been received or will be received related directly or indirectly to the subject of this article.

Corresponding author: Harvey Chim, MD, Division of Plastic Surgery, University of Miami Miller School of Medicine, Clinical Research Building, 1120 NW 14th Street, Fourth Floor, Miami, FL 33136; e-mail: harveychim@yahoo.com.

0363-5023/17/4201-0017\$36.00/0
<http://dx.doi.org/10.1016/j.jhssa.2016.11.008>

TABLE 1. Patient Data

Patient	Age, y	Gender	Mechanism of Injury	Preoperative Metacarpophalangeal Joint Range of Motion (degrees)	Length of Amputated Finger, cm	Defect Length Compared With Contralateral Finger, cm
1	31	Male	Crush	5	2.1	2.0
2	21	Male	Crush	20	2.3	1.8
3	29	Male	Crush	25	2.0	2.2

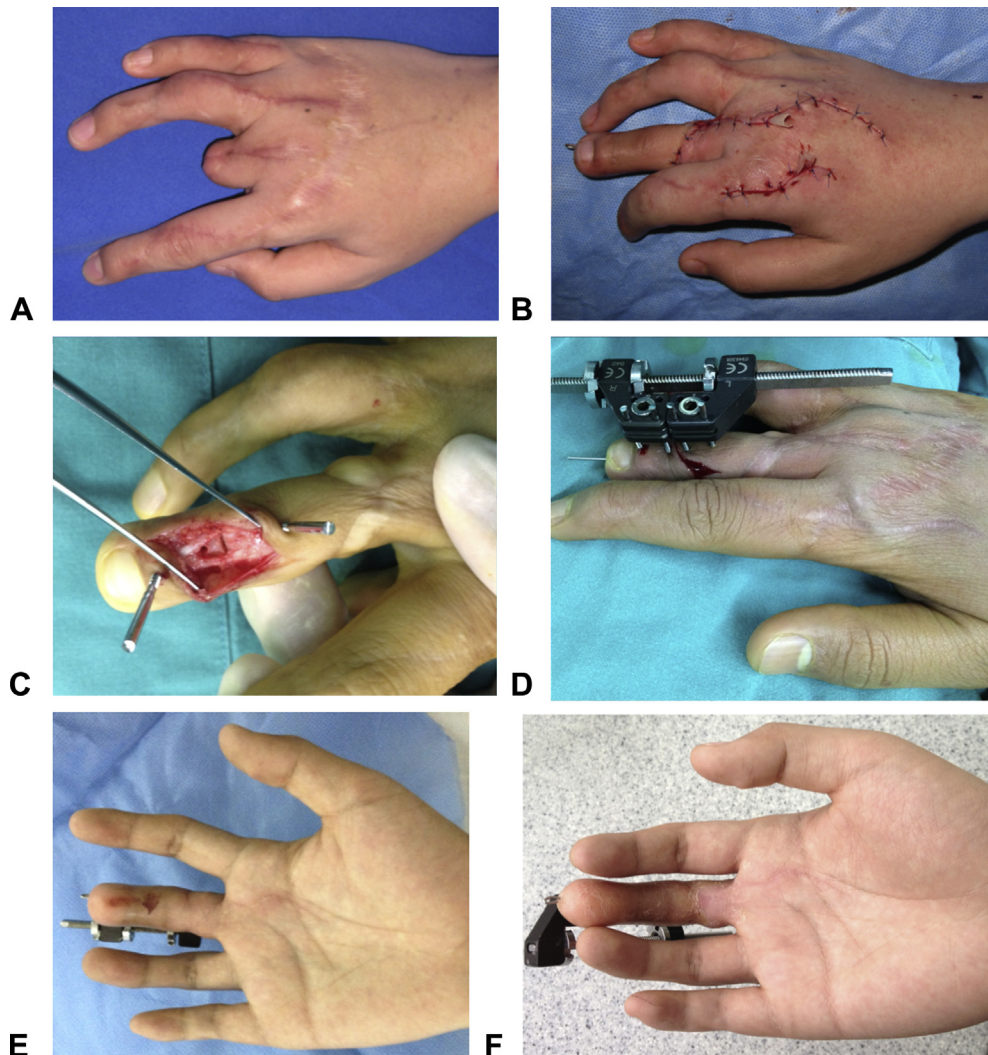


FIGURE 1: **A** Preoperative appearance in patient 1 showing middle finger amputated at the level of the proximal phalanx. **B** Appearance immediately after second toe transfer. There is a clear discrepancy in length between the reconstructed middle finger and the index and ring fingers. **C** Corticotomy of the middle phalanx is performed 6 months after second toe transfer. **D, E** Immediately after surgery, after application of external fixator. **F** Eight weeks after surgery, showing increase in length of middle finger after completion of distraction.

transfer results in a digit that is shorter than the adjacent digits. In the context of a middle finger amputation and reconstruction, this results in a particular problem because the index and ring fingers on either side of the middle finger are longer, which

affects the function of the hand and results in a noticeable deformity of the entire hand.

Distraction lengthening of nonvascularized toe phalanx transfers has been reported to enhance prehension in symbrachydactyly^{6,7} and other traumatic

متن کامل مقاله

دریافت فوری ←

ISIArticles

مرجع مقالات تخصصی ایران

- ✓ امکان دانلود نسخه تمام متن مقالات انگلیسی
- ✓ امکان دانلود نسخه ترجمه شده مقالات
- ✓ پذیرش سفارش ترجمه تخصصی
- ✓ امکان جستجو در آرشیو جامعی از صدها موضوع و هزاران مقاله
- ✓ امکان دانلود رایگان ۲ صفحه اول هر مقاله
- ✓ امکان پرداخت اینترنتی با کلیه کارت های عضو شتاب
- ✓ دانلود فوری مقاله پس از پرداخت آنلاین
- ✓ پشتیبانی کامل خرید با بهره مندی از سیستم هوشمند رهگیری سفارشات