



Operative Technique

Umbilical cord sparing technique for repair of congenital hernia into the cord and small omphalocele



Silvia Ceccanti, Ilaria Falconi, Simone Frediani, Alessandro Boscarelli, Layla Musleh, Denis A. Cozzi *

Paediatric Surgery Unit, Sapienza University of Rome, Azienda Policlinico Umberto I, Rome, RM 00161, Italy

ARTICLE INFO

Article history:

Received 23 May 2016

Received in revised form 6 September 2016

Accepted 11 October 2016

Key words:

Omphalocele
Exomphalos
Umbilical cord hernia
Scarless abdomen
Umbilicus
Ectopic liver

ABSTRACT

Background/Purpose: Current repair of small omphaloceles and hernias into the umbilical cord is a straightforward procedure, whose repair may result in a suboptimal cosmetic outcome. We describe a novel repair technique retaining the umbilical cord elements in an attempt to improve the cosmetic appearance of the umbilicus.

Methods: Eight neonates were consecutively treated more than a ten-year period. Size of the fascial defects ranged 1 to 3 cm (median, 2). Present technique entails incision of the amniotic sac without its detachment from the skin, reduction of the extruded contents under direct vision, and closure of the abdominal wall defect by circumferential suturing of peritoneum and fascia around the base of the amniotic sac. The amniotic sac is then re-approximated and folded to create an umbilical stump, which is trimmed and left to shed naturally.

Results: All patients achieved a scarless abdomen with a normal appearing umbilicus in 6. The remaining 2 patients are awaiting surgery for persisting umbilical hernia repair and umbilicoplasty, respectively. Poor esthetic outcome was significantly associated with initial fascial defect ≥ 2.5 cm in size ($p = 0.03$).

Conclusions: Present technique is a simple and cosmetically appealing repair for umbilical cord hernias and small omphaloceles, especially effective when the size of the fascial defect is less than 2.5 cm.

Level of evidence: IV (Treatment Study).

© 2017 Elsevier Inc. All rights reserved.

Omphalocele, i.e. exomphalos in British usage, is a congenital mid-line abdominal wall defect that results in herniation of intraabdominal contents into a sac covered by a lining of peritoneum and amniotic membrane. The severity of this malformation correlates well with the size of the defect. Conventionally, a defect size of 4 or 5 cm in maximum diameter is considered the watershed between small and large omphaloceles [1–3]. Given the similar surgical treatment, hernia into the umbilical cord is often inappropriately included among small omphaloceles, even though the 2 entities represent distinct ventral abdominal wall defects.

The operation most commonly performed to repair either a hernia into the umbilical cord or a small omphalocele entails excision of the amniotic sac flush with the skin, individual ligation of the umbilical vessels at the level of the peritoneum, fascial closure and reconstruction of the skin with a circumferential subcuticular purse-string suture [4,5]. However, this technique, despite being readily accepted, is often associated with a suboptimal cosmetic outcome owing to the lack of a normal looking umbilicus, which is instead characterized by the formation of a flat star-shaped umbilical scar.

Herein, we describe a simple method to repair a hernia into the umbilical cord and small omphalocele using a novel technique based

on preservation of the umbilical cord elements in an attempt to improve the cosmetic appearance of the umbilicus.

1. Material and methods

From January 2004 to June 2014, 26 consecutive neonates with congenital abdominal wall defects were treated at our institution under the care of a single surgeon (DAC). Clinical information was retrieved from our prospectively maintained database. Twelve patients with gastroschisis and 5 with omphalocele with a fascial defect greater than 4 cm were excluded from present study.

The defect of the remaining patients was classified as hernia into the umbilical cord in 4 and small omphalocele (i.e. fascial defect less than 4 cm) in five. One initial patient with hernia into the umbilical cord was excluded from the study because its repair was accomplished by the conventional technique using the purse-string skin closure umbilicoplasty. The remaining 8 patients underwent primary repair of their defect using a consistent new surgical technique. The size of the defect was measured either during physical examination at the time of initial assessment or during surgery. Measurements were obtained at the neck of fascial defect, without taking into account the greatest size of the amniotic sac. Data collection included patient demographics, associated anomalies, operative details and complications. The primary outcome measure of the study was the final appearance of the umbilicus, which was assessed at a special follow-up visit. Digital color

* Corresponding author at: Pediatric Surgery Unit, Policlinico Umberto I, Sapienza University of Rome, Viale Regina Elena, 324, 00161 Rome, Italy. Tel./fax: +39 06 499 79349.
E-mail address: da.cozzi@uniroma1.it (D.A. Cozzi).

photographs of the patients' abdomen were taken using a single camera in a standardized fashion. The cosmetic assessment consisted of a subjective evaluation performed by a 5-member panel that blindly scored the photographs using a four-point Likert scale – excellent, good, fair, and poor. The umbilicus was defined as “excellent” if it was characterized by a well-depressed and oval structure (“innie” umbilicus). The umbilical scar was described as “good” when the navel had a button-shaped appearance, which is characterized by a protuberant mass of scar tissue which fills and obliterates a well-formed depression (“outie” umbilicus). The third category was for umbilical scars described as “fair”, defined as an outie navel associated with a protruding umbilical hernia. The final category was for “poor” scars, defined as unsightly, visible hypertrophic, or hyperpigmented scars without any umbilical depression, and with or without associated umbilical hernia. For ease of calculation, we used the median score of the panel's assessments to obtain the final score for each patient. A satisfaction questionnaire was also administered to the family members, who were asked to rate their perception of the esthetic appearance of the umbilicus on a three-point scale – very satisfied, moderately satisfied, or not satisfied. The study was reviewed and approved by the appropriate institutional review board, and informed parental consent was obtained from all participating patients. The Mann–Whitney U test and Fisher's exact test were used for statistical comparison, as appropriate. Significance for all analyses was assessed at a p value of less than 0.05 (2-tailed). Continuous variables were expressed as median (range).

1.1. Operative technique

The operation is performed under general anesthesia. Complete viscera reduction is usually accomplished easily by gentle manual compression of the amniotic sac. A radial incision is then cautiously placed high onto the sac and converted in a circumferential fashion, excising most of the sac and leaving intact its base for approximately 1–2 cm from the skin edges (Fig. 1A,B). The remaining herniated contents are thoroughly inspected and, when present, adhesions to the sac are released (Fig. 1C). Exploration of the intra-abdominal gut is not routinely performed. The abdominal wall defect is then closed

with one or two stitches in a purse-string fashion using 3–0 or 4–0 absorbable suture material, securing the peritoneum and fascia underneath the edges of the amniotic sac, without undermining of skin from fascia (Fig. 1D). The remainder of the amniotic sac is then re-approximated and folded using the same absorbable suture material to create an umbilical stump, which is trimmed and left to shed naturally (Fig. 1E,F).

2. Results

Five of the 8 patients had their abdominal wall defect detected in utero. Table 1 summarizes the main clinical characteristics of our patients. Maximum diameter of the fascial defect ranged 1 to 3 cm (median, 2 cm). The median defect size of hernia into the umbilical cord was 1 cm (range, 1 to 1.5), and was significantly smaller than that of small omphaloceles [(2 cm; range, 2 to 3); $p = 0.03$]. In 7 patients, hernial sac contents were predominantly loops of small bowel, including also the cecum in 2, and a small portion of the liver edge attached to the base of the largest fascial defect of the series. The remaining patient was referred to our attention few days after birth for an umbilical mass prenatally detected. The umbilical cord appeared also markedly swollen. Following few days of antibiotic treatment, surgical exploration was carried out by using our transumbilical approach. The dried up outer side of hernial sac was opened circumferentially revealing a 15 × 15 mm dark red solid mass, which was dissected off a slightly enlarged umbilical ring (Fig. 2A,B). The lesion was communicating to the abdominal cavity through a long stalk becoming progressively thinner, which was blindly excised using bipolar diathermy without formal inspection of the abdominal cavity (Fig. 2C). The umbilical ring was then closed using present technique (Fig. 2D–F). Histology showed normal hepatic tissue leading to the diagnosis of ectopic liver within the umbilical cord. All patients had a smooth postoperative course with a median length of hospital stay of 7 days (range, 1 to 17). In 2 patients, intestinal malrotation was ruled out by means of upper GI contrast study and by intraoperative exploration, respectively. In the latter case, the fascial defect size (2.5 cm) was adequate to allow thorough exploration of the GI tract

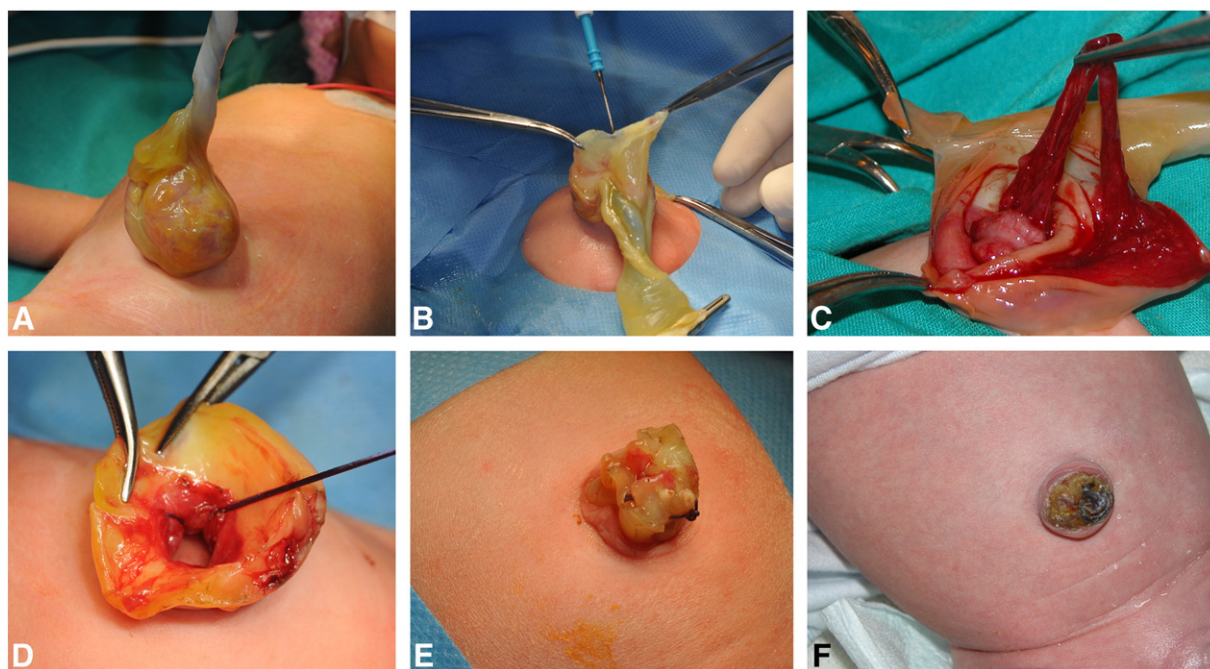


Fig. 1. Details of the surgical technique. A, Small omphalocele before reduction of amniotic sac contents. B, Initial incision of the amniotic sac. C, Release of adhesions between omentum and the sac. D, Closure of peritoneum and fascia using purse-string sutures placed through the umbilical skin defect, preserving the umbilical cord elements. E, Re-approximation and folding of the residual sac. F, The reconstructed umbilical stump is left to shed naturally.

متن کامل مقاله

دریافت فوری ←

ISIArticles

مرجع مقالات تخصصی ایران

- ✓ امکان دانلود نسخه تمام متن مقالات انگلیسی
- ✓ امکان دانلود نسخه ترجمه شده مقالات
- ✓ پذیرش سفارش ترجمه تخصصی
- ✓ امکان جستجو در آرشیو جامعی از صدها موضوع و هزاران مقاله
- ✓ امکان دانلود رایگان ۲ صفحه اول هر مقاله
- ✓ امکان پرداخت اینترنتی با کلیه کارت های عضو شتاب
- ✓ دانلود فوری مقاله پس از پرداخت آنلاین
- ✓ پشتیبانی کامل خرید با بهره مندی از سیستم هوشمند رهگیری سفارشات