



Contents lists available at ScienceDirect

## Current Medicine Research and Practice

journal homepage: [www.elsevier.com/locate/cmpr](http://www.elsevier.com/locate/cmpr)



Original article

### Gender reassignment surgery: Our experience of 20 cases

Anubhav Gupta\*, Bheem Nanda, Mahesh Mangal, Swaroop Gambhir, Sasidhar Reddy J

Department of Plastic & Cosmetic Surgery, Sir Ganga Ram Hospital, India

#### ARTICLE INFO

##### Article history:

Received 10 August 2017

Accepted 6 October 2017

Available online xxx

##### Keywords:

Gender identity disorder

Gender reassignment surgery

Sex change

#### ABSTRACT

**Introduction:** Gender Reassignment Surgery is a general term used to describe all procedures related to surgically converting patients of Gender identity disorder into their desired sex. This may be mastectomy, vaginectomy, penile reconstruction etc in female to male, or breast augmentation, vaginal reconstruction etc in male to female.

**Material and method:** We share our experience of twenty cases of Gender identity disorder operated over a period of seven years at our hospital with a minimum follow up of six months

**Results:** The most commonly done procedure was mastectomy in female to male sex change followed by vaginal reconstruction in male to female.

**Conclusion:** Gender identity disorder is becoming increasingly common nowadays with patients coming forward for surgical intervention. These patients need a sensitive approach and teamwork between the Plastic Surgeon, Psychiatrist, Gynecologist and the Endocrinologist.

© 2017 Published by Elsevier, a division of RELX India, Pvt. Ltd on behalf of Sir Ganga Ram Hospital.

#### 1. Introduction

Gender identity issues have been present across the ages for longer than we can ever imagine. There is a popular Greek mythological story about a woman raised as a male falling in love with another woman, and being transformed into a man just before their wedding.<sup>1</sup>

Indian Mythology also has numerous references to altered sexual state. *Ardhnarishwara* refers to God, who is half man and half woman, an androgynous deity. In Mahabharata, *Arjuna*, spent a month in an intersex state during the *agyatvaas* period. *Shikhandini*, the killer of *Bhishma* was born female, but raised like a man and trained in warfare.<sup>2</sup>

Aberrant sexual conditions like homosexual, fetishism, gender identity disorder, and associated conditions were mixed together and regarded as types of sexual perversion that were considered ethically objectionable until the 1950s. However, the performance of first sex-reassignment surgery in 1952 attracted considerable attention and the term transsexualism<sup>1</sup> was coined by Harry Benjamin.

The transsexual phenomenon is no longer limited to bookish references and is now being increasingly observed and treated by the medical fraternity.

Transsexuality can be understood if we are able to differentiate between SEX and GENDER. Sex represents physical differentiation as male or female, due to the external appearance of genitalia and the presence of gonads, 'Gender' is the psychological recognition of self such as boy/man or girl/woman. In short, sex is what one is seen as and gender being what one feels.<sup>3</sup> The feeling of incongruence between sex and gender is termed gender dysphoria. Transsexualism is the most extreme form of this disorder. There are many terms coined for sex change surgery, such as sex reassignment surgery, gender reassignment surgery, sex affirmation surgery, and feminizing or masculinizing genitoplasty.

The exact cause of gender identity disorder is not known. But the contributing factor may be: **Hormonal** –Sex hormones like Progesterins taken during pregnancy may influence behavior of child **Environmental** –Parents noticing signs of Gender Identity Disorder unknowingly encourage such behaviors. Children are easily influenced and may pick up certain habits and behavior patterns from the surrounding people.

The prerequisites for Gender affirmation surgery are to have a confirmed diagnosis<sup>4</sup> based on the following criteria:

1. A sense of incongruence between one's expressed gender and primary & secondary sex characters.
2. A wish to be rid of one's genitalia and the desire to live life as a member of the opposite sex.
3. This discomfort/disturbance has been continuously present for a minimum of six months and is not limited to a period of stress.
4. An absence of physical intersex of genital abnormality.

\* Corresponding author.

E-mail addresses: [anubhavgupta1976@gmail.com](mailto:anubhavgupta1976@gmail.com) (A. Gupta), [bheemnanda@gmail.com](mailto:bheemnanda@gmail.com) (B. Nanda), [mc\\_mangal@hotmail.com](mailto:mc_mangal@hotmail.com) (M. Mangal), [swaroopg@gmail.com](mailto:swaroopg@gmail.com) (S. Gambhir), [j.sasidharreddy@gmail.com](mailto:j.sasidharreddy@gmail.com) (S. Reddy J).

<https://doi.org/10.1016/j.cmpr.2017.10.001>

2352-0817/© 2017 Published by Elsevier, a division of RELX India, Pvt. Ltd on behalf of Sir Ganga Ram Hospital.

## 5. Absence of a mental disorder such as Schizophrenia.

Assessment by two independent psychiatrists at two different times and certification of the diagnosis by them is mandatory to proceed further for gender surgery. However, hormonal therapy initiation and breast surgery may be done after certification from one psychiatrist also.

The certification letter from the Psychiatrist should include<sup>2</sup> identifying characteristics of the patient, initial gender, duration of treating the patient, eligibility criteria, rationale for hormonal therapy and confirmation of the diagnosis

Once the diagnosis is confirmed, the person is advised to cross dress in the society and after completing 6 months of such living he is referred to an Endocrinologist for hormonal therapy. Patient is duly explained and counseled about the long term effects of hormonal therapy before starting it.

Once the patient has spent adequate time cross dressing and taking hormonal therapy surgical intervention is planned. Since the Indian laws are silent on the issue of legality of Gender surgery, it is now a protocol to have an affidavit duly signed by the patient and a witness before undertaking these surgeries.

Gender reassignment surgery in Male to Female comprises of:

- (i) Genital surgery- Orhidectomy + Vaginal Reconstruction (Penile skin inversion technique)
- (ii) Breast augmentation
- (iii) Genioplasty
- (iv) Rhinoplasty
- (v) Vocal cord surgery for Voice
- (vi) Laser for hair removal

Mcindoe's Vaginoplasty (Skin Graft)

Gender reassignment surgery in Female to Male comprises of:

- (i) Mastectomy
- (ii) Hysterectomy
- (iii) Phallus creation by Radial Artery Forearm Free Flap
- (iv) Testicular implants
- (v) Penile Implant for Erectile function
- (vi) Vocal cord surgery for Voice
- (vii) Hair Transplant for Moustache & Beard

## 2. Material and methods

Over a period of last 7 years we have operated 20 cases of Gender Identity disorder with a minimum follow up of six months. Five cases were male to female, while fifteen cases were of female to male (Fig. 1).

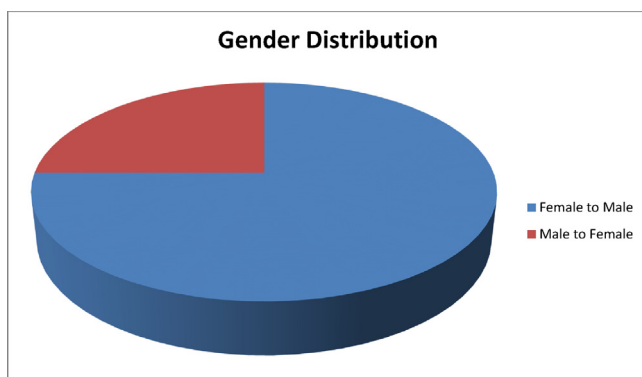


Fig. 1. Gender distribution in Sex change patient population.

All patients were operated on an indoor basis at our institute under general anaesthesia. Usually, the mastectomy patients were discharged on the same day while those of vaginal reconstruction were kept for a couple of days. The maximum hospital stay was for penile reconstruction patient who was kept for a week. These patients were followed up for a minimum of six months with maximum being five years.

Two patients of Male to female were operated for the complete set of surgeries like Genital surgery- Orhidectomy + Vaginal Reconstruction (Penile skin inversion technique), Breast augmentation, Genioplasty, Rhinoplasty, Vocal cord surgery for Voice and Laser for hair removal. After completion of the treatment both the patients were found to be successfully accepted in their new roles by the society and one of them is in an active relationship.

One patient of female to male transfer was operated for the complete set of surgeries like Mastectomy, Hysterectomy, Phallus creation by Radial Artery Forearm Free Flap, Penile Implant for Erectile function and Vocal cord surgery for Voice. He has also been accepted in his new role by the society and is currently working in a multinational company.

## 3. Result and discussion

The commonest surgery we have performed is mastectomy for the female to male patients followed by vaginal reconstruction (Fig. 2). The reason for the female to male bias, (that is more patients of Female to Male), is probably because of the patriarchal society model we have, with an underlying desire to be a dominant being, having a say in this choice.

We did twelve Mastectomies by the subcutaneous –free nipple graft technique (Fig. 3). The position of the new nipple was decided pre operatively with the patient in standing position usually along the lateral border of the pectoralis Major muscle at the level of the fifth rib.<sup>5</sup> The size was reduced to 2.5 cms in diameter. We started doing routine liposuction of the flanks and infra mammary fold region after the initial two cases as we noticed residual bulges in the flanks post surgery in standing position. Post surgery we advised all these patients to wear a pressure garment for atleast 3 months.

Ironically, two third of these patients never returned for further surgeries. On follow up it was found that most of them were no longer interested in gender surgery mainly because of lack of funds. These patients were content with the removal of breasts as it helped them in their cross dressing and living in the society. This along with the hormonal therapy was enough for them to successfully disguise as males. We did one penile reconstruction with Free Radial Artery Forearm Flap (RAFF) technique using a temporary ArterioVenous loop<sup>6</sup>. Surgery was performed by two teams simultaneously in which 1 team harvested the flap and modeled the penile construct while the other team prepared the av loop and the recipient site. The av loop was made by joining the great saphenous vein to the femoral artery by an end to side anastomosis. The penile construct was designed with Urethral tube lying on the non hair bearing side of the forearm i.e. more towards Ulnar border. The patient was kept in the hospital for 5 days post operatively after which he was discharged. The indwelling urethral catheter was removed after 2 weeks of surgery. The patient was able to urinate while standing after removal of catheter and developed sensations<sup>8</sup> in the reconstructed penis after 18 months of surgery (Fig. 4). He was able to achieve orgasm by stimulating the base of the neo penis after return of sensations. Later a static penile implant was inserted in the sensate organ. Patient however was not satisfied and requested self inflatable implant which could not be done owing to cost issues.

Amongst Male to female, we did gender surgery in three cases out of five. In two cases, face surgery in the form of Genioplasty

متن کامل مقاله

دریافت فوری ←

**ISI**Articles

مرجع مقالات تخصصی ایران

- ✓ امکان دانلود نسخه تمام متن مقالات انگلیسی
- ✓ امکان دانلود نسخه ترجمه شده مقالات
- ✓ پذیرش سفارش ترجمه تخصصی
- ✓ امکان جستجو در آرشیو جامعی از صدها موضوع و هزاران مقاله
- ✓ امکان دانلود رایگان ۲ صفحه اول هر مقاله
- ✓ امکان پرداخت اینترنتی با کلیه کارت های عضو شتاب
- ✓ دانلود فوری مقاله پس از پرداخت آنلاین
- ✓ پشتیبانی کامل خرید با بهره مندی از سیستم هوشمند رهگیری سفارشات