



ELSEVIER

ORIGINAL ARTICLE

Single lateral versus medial and lateral plates for treating displaced scapular body fractures: a retrospective comparative study

Rongguang Ao, MD, Baoqing Yu, MD*, Yalong Zhu, MD, Xinhua Jiang, MD, Jifei Shi, MD, Jianhua Zhou, MD

Department of Orthopedics, Shanghai Pudong Hospital, Fudan University Pudong Medical Center, Shanghai, China

Background: This study compared the outcomes and complications of single lateral plating vs. dual plating for treating displaced scapular body fractures.

Methods: Open reduction and internal fixation using locking plates was performed in 45 patients with displaced scapular fractures. A single lateral plate fixed in the lateral border was used in 22 patients (group A), and dual plates fixed in both the lateral and medial borders were used in 23 (group B).

Results: The average follow-up duration in both groups was 20 months. A remarkable difference was seen between the 2 groups in mean operative time and blood loss, although the Disabilities of the Arm, Shoulder and Hand and Constant Shoulder scores at the final follow-up were similar. The prominence rate of the hardware was 27.3% (6 of 22) in group A and 65.2% (15 of 23) in group B. The plate removal rate was 31.8% (7 of 22) in group A and 78.3% (18 of 23) in group B.

Conclusions: Open reduction using a single plate on the lateral border for treating displaced scapular body fractures can lead to good functional outcomes, shorter operative time, less blood loss, and fewer plate-related complications compared with the dual-plating technique.

Level of evidence: Level III; Retrospective Cohort Design; Treatment Study

© 2017

Keywords: Scapular fracture; body fracture; open reduction; internal fixation; single plate; dual plate

Scapular fractures are rare, accounting for 0.7% of all the fractures and 3% to 5% of upper extremity fractures,^{2,13} and are often caused by high-energy injury. Nearly 50% of the scapular fractures involve the scapular body and spine.¹² Compared with conservative treatment, operative management may achieve superior functional results and decrease the rate of

symptomatic malunion and nonunion for displaced scapular body fractures.⁹

Cole and colleagues^{3,8,10,15} recommend surgical treatment in obviously displaced scapular body and neck fractures with >20 mm of medial/lateral (M/L) displacement, >45° of angular deformity on a scapular Y-view X-ray, the combination of angulation of >30° plus M/L displacement of >15 mm, double disruptions of the superior shoulder suspensory complex both displaced >10 mm, and a glenopolar angle (GPA) of <22°. According to this indication, several operative studies for treating displaced scapular body fractures have been reported, and good outcomes were achieved with surgical treatment.

The Shanghai Pudong Hospital Human Research Ethics Committee approved this study (Approval No. 2016018) on December 4, 2016.

*Reprint requests: Baoqing Yu, MD, Department of Orthopedics, Shanghai Pudong Hospital, Fudan University Pudong Medical Center, 2800 Gongwei Rd, Huinan Town, Pudong, Shanghai 201399, China.

E-mail address: 13131310044@fudan.edu.cn (B. Yu).

The number plates necessary to fix the scapular body fracture has not yet been determined, however. Owing to the subcutaneous position of the medial and spine border, implant-related complications, including plate prominence and removal, may be higher when the medial border is fixed with plates.

In this study, operative time, blood loss, functional outcome at final follow-up, and plate-related complications of fixation with a single lateral plate were compared with dual plates for treating displaced scapular body fractures.

Materials and methods

General data

This retrospective case-control study included 50 patients with displaced scapular body fractures treated between October 2010 and May 2014. Inclusion criteria were, first, all patients indicated for surgery fulfilled at least 1 of the following operative criteria: ≥ 20 mm M/L displacement, $\geq 45^\circ$ of angular deformity, the combination of angulation $\geq 30^\circ$ plus M/L displacement ≥ 15 mm, and double disruption of the superior shoulder suspensory complex with both displaced ≥ 10 mm. These measurements were guided by the Anavian et al¹ study based on the radiographic measurement technique for extra-articular scapular fractures. Second, the period between injury and surgery was ≤ 21 days. Third, the lateral border fracture could be reconstructed and fixed by a single plate. The exclusion criteria were a scapular body fracture associated with glenoid, coracoid, or acromion fracture and a scapular fracture > 21 days after injury.

According to the classification introduced by Bartoníček et al,³ 15 patients presented with high transverse fractures, 14 with low transverse fractures, 6 with 3-fragment fractures, and 4 with comminuted fractures; in addition, 3 patients presented with high transverse combined with surgical neck fractures and 3 patients with 3-fragment combined with surgical neck fractures. Fig. 1 illustrates the scapular body fracture classification introduced by Bartoníček.

After a discussion with the patient and his or her relatives, surgeons made the choice of plate, a decision determined by a combination of fracture characteristics and the patient's financial resources. Two patients in group A and 3 in group B failed to have a follow-up. Therefore, the study comprised 45 patients with displaced scapular body fractures who underwent open reduction and internal fixation using locking plates, including a 3.5-mm or 2.7-mm locking plate for the lateral border and a 2.7-mm locking plate for medial border. Single plates were used in 22 patients and dual plates in 23. The follow-up time, age, sex distribution, fracture type, the cause of the injuries, and associated injuries in the 2 groups are listed in Table I.

Surgical technique and rehabilitation

The procedure was performed with the patients under general anesthesia and in lateral decubitus via the modified Judet approach.

In group A, the lateral straight incision or reversed L-shaped incision was fashioned. The lateral border fracture of the scapula was exposed in the interval between the teres minor and infraspinatus muscles. Then, reduction and internal fixation of the lateral border was conducted under direct visualization. We used 2 clamps to grasp the cephalad fragment and the distal segment and amended the lateral

Table I General conditions

Variable ^a	Group A (n = 22)	Group B (n = 23)
Gender		
Male	12	12
Female	10	11
Age, y	38.0 \pm 10.5	40.5 \pm 11.0
Cause		
Traffic accident	15	16
Direct hit	4	4
Fall	3	3
Fracture type		
2L	7	8
2H	7	7
3F	3	3
Comminuted	2	2
Combined (2H + SN)	2	1
Combined (3F + SN)	1	2
Ipsilateral shoulder girdle injuries		
Clavicle fracture	3	4
Acromioclavicular dislocation	1	1
Follow-up duration	19.5 \pm 3.5	20.6 \pm 3.0

2L, 2-fragment low transverse fracture, 2H, 2-fragment high transverse fracture, 3F, 3-fragment fracture, SN, surgical neck fracture.

^a Data are shown as number or mean \pm standard deviation.

and angulation displacement. Consecutively, a 3.5-mm or 2.7-mm locked reconstruction plate was placed on the lateral border after remolding. We suggest that at least 3 screws should be used to secure the fixation on each side of the fracture line. If segmental fractures

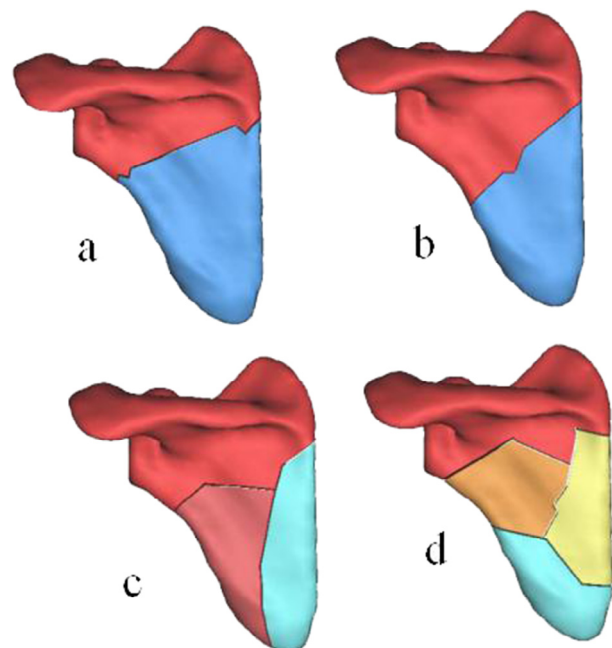


Figure 1 Illustration shows the classification of scapular body fractures introduced by Bartoníček: (a) 2-fragment high transverse fracture, (b) 2-fragment low transverse fracture, (c) 3-fragment fracture, and (d) comminuted fracture.

متن کامل مقاله

دریافت فوری ←

ISIArticles

مرجع مقالات تخصصی ایران

- ✓ امکان دانلود نسخه تمام متن مقالات انگلیسی
- ✓ امکان دانلود نسخه ترجمه شده مقالات
- ✓ پذیرش سفارش ترجمه تخصصی
- ✓ امکان جستجو در آرشیو جامعی از صدها موضوع و هزاران مقاله
- ✓ امکان دانلود رایگان ۲ صفحه اول هر مقاله
- ✓ امکان پرداخت اینترنتی با کلیه کارت های عضو شتاب
- ✓ دانلود فوری مقاله پس از پرداخت آنلاین
- ✓ پشتیبانی کامل خرید با بهره مندی از سیستم هوشمند رهگیری سفارشات