



Contents lists available at ScienceDirect

Medical Engineering and Physics

journal homepage: www.elsevier.com/locate/medengphy

Spring assisted cranioplasty: A patient specific computational model

Alessandro Borghi*, Naiara Rodriguez-Florez, Will Rodgers, Gregory James, Richard Hayward, David Dunaway, Owase Jeelani, Silvia Schievano

UCL Great Ormond Street Institute of Child Health, 30 Guilford Street, London WC1N 1EH

ARTICLE INFO

Article history:

Received 29 January 2017

Revised 19 December 2017

Accepted 3 January 2018

Available online xxx

Keywords:

Craniosynostosis

Spring cranioplasty

Finite element modeling

ABSTRACT

Implantation of spring-like distractors in the treatment of sagittal craniosynostosis is a novel technique that has proven functionally and aesthetically effective in correcting skull deformities; however, final shape outcomes remain moderately unpredictable due to an incomplete understanding of the skull-distractor interaction.

The aim of this study was to create a patient specific computational model of spring assisted cranioplasty (SAC) that can help predict the individual overall final head shape. Pre-operative computed tomography images of a SAC patient were processed to extract a 3D model of the infant skull anatomy and simulate spring implantation. The distractors were modeled based on mechanical experimental data. Viscoelastic bone properties from the literature were tuned using the specific patient procedural information recorded during surgery and from x-ray measurements at follow-up. The model accurately captured spring expansion on-table (within 9% of the measured values), as well as at first and second follow-ups (within 8% of the measured values). Comparison between immediate post-operative 3D head scanning and numerical results for this patient proved that the model could successfully predict the final overall head shape.

This preliminary work showed the potential application of computational modeling to study SAC, to support pre-operative planning and guide novel distractor design.

© 2018 Published by Elsevier Ltd on behalf of IPPEM.

1. Introduction

Craniosynostosis is a rare disease affecting 1 in 1700 live births consisting in premature fusion (ossification) of one or more cranial sutures during infancy [1]. The most common presentation is sagittal craniosynostosis, which occurs when the sagittal suture fuses, causing scaphocephaly – a craniofacial deformity described by long narrow heads (Fig. 1) – and in some cases, raised intracranial pressure with functional problems [2–4].

Treatment options for craniosynostosis include extensive surgical procedures such as total cranial vault remodeling [5] and strip craniectomy [6], or less invasive endoscopic approaches [7]. In 1998, a new technique for treating scaphocephaly was first reported by Lauritzen et al. with the use of spring devices [8]. In his procedure, bony cuts were performed to free the fused suture and metallic springs were placed on the osteotomy borders to widen the skull over a few weeks gradually remodeling it.

Since then, clinical studies have shown no difference in efficacy and safety of SAC compared to traditional surgical techniques [9], but have reported considerably lower blood loss, transfusion re-

quirement and overall hospital cost in the case of SAC [10]. The main clinical criticism of SAC is the lack of long-term morphological outcome data and the need for a second operation to remove the springs and, therefore, for a second general anesthesia. A technical limitation of current devices is the lack of control on spring action, available for other types of distractors [11], which can in some patients result in suboptimal outcomes such as under-correction and coronal or lambdoid ridging [12]. The main reasons for these are still unclear, potentially depending on many different factors, such as severity of the disease, patient age and relative bone formation, spring positioning on the skull and choice of spring model, with no consensus yet achieved [8,12].

Patient specific computational modeling, able to replicate each individual characteristics and take into account many different external factors, represents an ideal tool to study this complex problem, provide quantitative assessment of surgical outcomes and potentially help planning the procedure.

Different approaches are described in the literature that attempt to create patient-specific models of the skull for virtual surgical 3D simulation and planning, mostly focusing on adult cases, and with each method designed and developed for a different application. The starting point common to all approaches is the post-processing of pre-operative CT imaging datasets as this accurately

* Corresponding author.

E-mail address: a.borghi@ucl.ac.uk (A. Borghi).

scaphocephaly

normocephaly

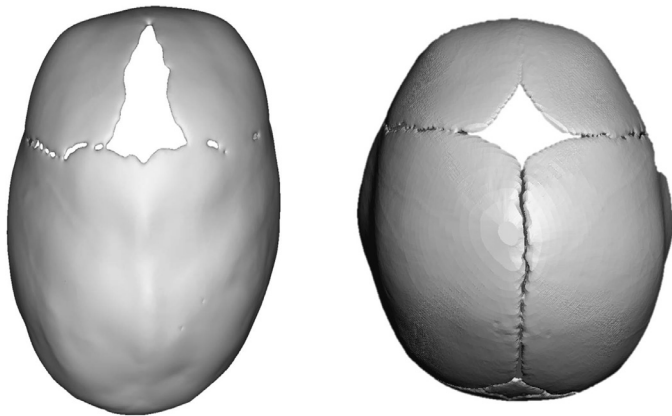


Fig. 1. Skull shape in sagittal craniosynostosis (scaphocephaly, left) compared to normal (normocephaly, right). The fusion of the sagittal suture is visible in the skull affected by scaphocephaly.

provides the anatomy of each specific individual. The methods then differ in terms of modelling of the bone and soft tissue properties, with structures mostly treated as rigid bodies – 3D translations and rotations are rigidly prescribed – to simulate craniofacial reshaping achieved by means of external rigid distractors [13,14]. Recent developments in the field have addressed soft tissue displacement as an effect of rigid translation on underlying tissues using thin plate spline interpolation [15,16]; however the accuracy of such methods, which ignore tissue extensibility and compressibility and only ensures continuity of displacement, is still debated [17,18]. Latest attempts to include the physical behavior of soft and hard tissue through FE modelling of the skull have proven to provide better results [19–22] than previous approaches, with one study also focusing on sagittal SAC [23] with the aim of predicting the expansion force in a cohort of scaphocephalic patients treated with springs: the model was able to capture the on-table spring performance with expansion forces within 10% of the on-table measurements. The region of interest was however limited to the calvarial strip relative to the osteotomy border and, therefore, the model was unable to predict the final skull shape over time.

In this work, a computational model of spring cranioplasty was built which included infant specific anatomy and material properties purposely tuned using spring opening information from a SAC patient. Serial 3D surface imaging of the patient head was used to validate the computational results, thus demonstrating feasibility and the potential of such methodology.

2. Methods

2.1. SAC procedure

In 2008, SAC was introduced at Great Ormond Street Hospital for Children (GOSH), London, UK, with a different distractor design (Fig. 2a) [24] compared to that proposed by Lauritzen [8,25] and a standardized surgical procedure in order to ensure result reproducibility [26]. Three different spring models (S10, S12 and S14) are available with same geometry, but different wire size (1.0, 1.2 and 1.4 mm, respectively) hence varying stiffness (0.17, 0.39 and 0.68 N/mm, respectively, Fig. 2b) [26]. At GOSH, SAC is used for correction of scaphocephaly in sagittal craniosynostosis, in children from 3 to 8 months of age. During the procedure, an incision is

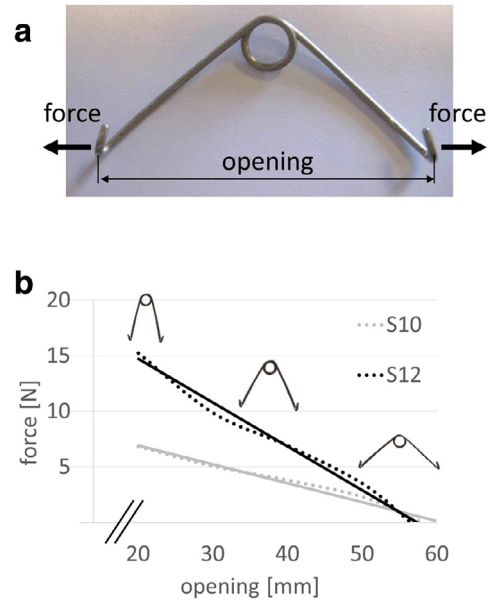


Fig. 2. (a) Cranioplasty spring used at GOSH (b) Unloading curves for the two spring models used in the patient in this study (S10, S12).

made on the patient scalp perpendicular to the sagittal suture. A square craniectomy is performed, approximately halfway along the fused sagittal suture, and two parasagittal osteotomies are made at a distance LAT from each other and parallel to the midline, starting from the craniectomy site and extending to the coronal sutures anteriorly and the lambdoid sutures posteriorly (Fig. 3). Two pairs of grooves are created on the osteotomy lines at a distance A and P from the coronal suture (Fig. 3) for the insertion of the anterior and posterior spring. Spring strength selection is made on-table according to clinical assessment of the calvarial bone quality and desired expansion. Measurement of LAT, A, P, spring models and on-table opening of the springs are recorded before closure of the wound. After surgery, patients are followed up with x-rays at day 1 (FU1) and after three weeks (FU2), before spring removal is carried out approximately 3–6 months from insertion.

2.2. Patient selection and image analysis

A 5.5 month old boy treated with SAC (S10 anteriorly and S12 posteriorly) at GOSH in 2014 was retrospectively selected for this study as he had pre-operative computed tomography (CT) images (age at scan = 4.4 months). CT data were post-processed (ScanIP, Synopsis, Mountain View, CA, USA) to create a patient specific geometrical 3D model of the skull: a combination of grey level thresholding and morphological operations was performed to isolate the hard tissue (the skull) from the soft tissues (fontanelle, coronal sutures and lambdoid suture, Fig. 3). The geometry was cut with a horizontal plane above the orbits, and slightly scaled to adjust for the growth of the patient between the time of the CT scan and the time of the operation (= 1.1 months) using dimensions from a pre-operative 3D surface scan acquired at the time of surgery (more information below). Bony cuts were replicated in the model (ScanIP, Simpleware, Exeter UK) to simulate the surgical procedure (Fig. 3) including the grooves corresponding to the spring insertion sites, according to the measurements and information recorded for this patient in theatre (LAT = 2.0 cm, A = 3.4 cm P = 5.3 cm).

Opening of the springs was measured from the x-ray images at follow-ups (FU1 = 1 day and FU2 = 22 days) after calibration [27].

متن کامل مقاله

دریافت فوری ←

ISIArticles

مرجع مقالات تخصصی ایران

- ✓ امکان دانلود نسخه تمام متن مقالات انگلیسی
- ✓ امکان دانلود نسخه ترجمه شده مقالات
- ✓ پذیرش سفارش ترجمه تخصصی
- ✓ امکان جستجو در آرشیو جامعی از صدها موضوع و هزاران مقاله
- ✓ امکان دانلود رایگان ۲ صفحه اول هر مقاله
- ✓ امکان پرداخت اینترنتی با کلیه کارت های عضو شتاب
- ✓ دانلود فوری مقاله پس از پرداخت آنلاین
- ✓ پشتیبانی کامل خرید با بهره مندی از سیستم هوشمند رهگیری سفارشات