




Contents lists available at ScienceDirect

American Journal of Otolaryngology–Head and Neck Medicine and Surgery

journal homepage: www.elsevier.com/locate/amjoto

A novel technique for superior-based pharyngeal flaps: 10-year results with formal speech outcomes assessment☆

Ryan Winters*, John Carter, J. Lindhe Guarisco

Ochsner Clinic Foundation Department of Otolaryngology – Head & Neck Surgery, New Orleans, LA, USA

ARTICLE INFO

Article history:

Received 9 September 2017
Available online xxx

Keywords:

Velopharyngeal insufficiency
Superior-based pharyngeal flap
Palatoplasty
Dysphonia

ABSTRACT

Purpose: Describe a novel technique for superior-based pharyngeal flaps allowing restoration of bulk to the soft palate and intraoperative fine-tuning of lateral port size, while avoiding midline palate-splitting. Validated speech assessment tools are employed for quantitative analysis.

Methods: Retrospective review of all patients who underwent superior-based pharyngeal flap in a 10-year period by a single surgeon. Pittsburgh Weighted Values for Speech Symptoms Associated with VPI and the Goldman-Fristoe Test of Articulation were used for formal speech assessment.

Results: 78 patients met inclusion criteria with clinical data up to 10 years postoperatively. 31 patients had congenital velopharyngeal insufficiency (VPI), and the remainder acquired VPI after cleft palate repair or adenoidectomy. 37 patients had a recognized syndrome. All patients noted subjective improvement in nasality, and evaluation with the validated speech assessment tools demonstrated statistically significant improvement in speech. Only one flap takedown was required in a patient with severe midface hypoplasia who developed sleep apnea several years postoperatively.

Conclusions: This technique is successful in congenital and acquired VPI, and in patients with complex craniofacial syndromes. Customization of lateral ports based on preoperative nasopharyngoscopy, and avoidance of a midline palate splitting incision, make this an attractive option for superior-based flap surgery.

© 2017 Published by Elsevier Inc.

1. Introduction

The velopharyngeal sphincter is formed by the velum, the lateral pharyngeal walls, and the posterior pharyngeal wall. Defects in the normal closure of the sphincter result in a reduced intelligibility of overall speech due to unwanted air escape through the nose during phonation. While addressing the speech of child is a multidisciplinary task, the aspects of nasal escape and resulting hypernasality can only be definitively corrected surgically.

Initial attempts at pharyngoplasty were first attributed to Passavant by suturing the posterior pharyngeal wall to the soft palate. Later the posterior pharyngeal flap was described by Schoenborn, as an inferiorly based flap. He changed this technique to a superiorly based flap in 1886 [1–3]. Hogan in 1973 emphasized widely based flaps, and introduced the lateral port control concept. Furthermore, he discussed lining the

superiorly based flap with flaps from the nasal mucosal surface to improve flap contour and healing [1,4]. Finally, Shprintzen instigated a paradigm shift away from a standard posterior flap to tailor-made pharyngeal flaps with width based on the amount of lateral pharyngeal wall motion observed preoperatively on videofluoroscopy and nasopharyngoscopy [1,4].

We present a novel modification of the superiorly based pharyngeal flap, which avoids the midline splitting of the soft palate. While this is a simple variation, it avoids disruption of otherwise intact functional palatal anatomy, and yields excellent and sustainable results.

2. Methods

After obtaining Institutional Review Board approval, records of all patients treated with superiorly-based pharyngeal flaps at the Ochsner Clinic Foundation in the preceding 10 years were reviewed. Basic demographic data, indication for the superiorly-based pharyngeal flap, presence of concomitant clinical syndromes, history of cleft lip or palate, and any early or late postoperative complications were recorded. Standardized speech assessment tools were employed, including the Pittsburgh Weighted Values of Speech Symptoms Associated with VPI (PWV) and the Goldman-Fristoe Test of Articulation (GFT). Data were

☆ The authors have no financial conflicts of interest to disclose, and all funding for the project was from Tulane University and Ochsner Clinic Foundation Department of Otolaryngology – Head & Neck Surgery Resident Research Funds. These data have been presented, in abstract form only, at the American Society of Pediatric Otolaryngology Meeting in Alexandria, VA, 2013.

* Corresponding author at: Ochsner Health System, Department of Otorhinolaryngology, 1514 Jefferson Hwy., New Orleans, LA 70121, USA.

E-mail address: ryan.winters@ochsner.org (R. Winters).

analyzed with Student's *t*-test, and a paired test was used when appropriate.

2.1. Operative technique

After obtaining informed consent from the patient's parent(s), the patient was taken to the operating room and general endotracheal anesthesia was induced via an orotracheal route. A shoulder roll was placed to extend the neck and maximize visibility, and the Dingman mouth gag was inserted and suspended from the Mayo stand. Indirect laryngoscopy was then performed with a dental mirror to assess the nasopharynx and any adenoid tissue. The superiorly-based pharyngeal flap was then outlined with methylene blue. Vertical incisions were then made in the posterior pharyngeal mucosa with a #15 blade, carried down to the prevertebral fascia. These incisions were then connected with a horizontal incision in the posterior pharyngeal mucosa opposite the larynx, and the resultant superiorly-based flap was elevated up to the level of C1.

The free edge of the soft palate is then incised with a cleft palate blade and right-angle scissors, bivalving the uvula and soft palate in a "fishmouth" fashion resulting in a 1.5 cm pocket. The flap was then inset in three layers. First, the superior portion of the soft palate was attached to the free margin of the superiorly-based pharyngeal flap with 4-0 Vicryl sutures in a simple interrupted fashion (Fig. 1A). The next layer of horizontal mattress sutures, also 4-0 Vicryl, attached the muscular portion of the flap into the depth of the recipient pocket, resulting in a bulky ridge of muscle and soft tissue (Fig. 1B). The final layer of 4-0 Vicryl sutures tacked the free margin of the superiorly-based pharyngeal flap and uvula to the raw surface of the flap (Fig. 1C). Each layer

required 3-4 individual sutures. The patency of the lateral ports was then assessed with indirect nasopharyngoscopy, and the donor site was closed, tacking the tissues to the posterior pharyngeal wall with 4-0 Vicryl sutures (Fig. 1D). The ports were again checked after donor site closure, and if found to be narrowed, the donor site was opened by removing sutures until the ports regained their necessary patency. Often at least partial closure was possible but, in the case of very wide flaps, the donor site can be left open to heal by secondary intent.

Copious saline irrigation was then undertaken to facilitate inspection and ensure hemostasis, and a 3-0 silk stay suture was placed into the tip of the tongue. The patient was then awakened in the operating room and transported to the Pediatric Intensive Care Unit for observation.

3. Results

Initial review identified 78 patients having undergone superiorly-based pharyngeal flaps in the prior 10 years. One was subsequently excluded from the study, as the pharyngeal flap was performed as a part of a complex oropharyngeal reconstruction for squamous cell carcinoma, rather than for VPI, leaving a total of 77 patients meeting inclusion criteria.

Patient ages ranged from 3 to 35 years old (mean 6.58 years old). Indications for superiorly-based pharyngeal flap included congenital VPI (31 patients), VPI after prior surgical closure of cleft palate (23 patients), VPI after prior adenoidectomy (22 patients), and VPI secondary to muscular dystrophy (1 patient). Thirty-seven patients carried a syndromic diagnosis (Table 1), while 40 patients had no identified clinical or genetic syndrome. Forty patients had cleft lip/palate (17 submucosal, 11 unilateral incomplete, 9 unilateral complete, 3 bilateral complete); and this

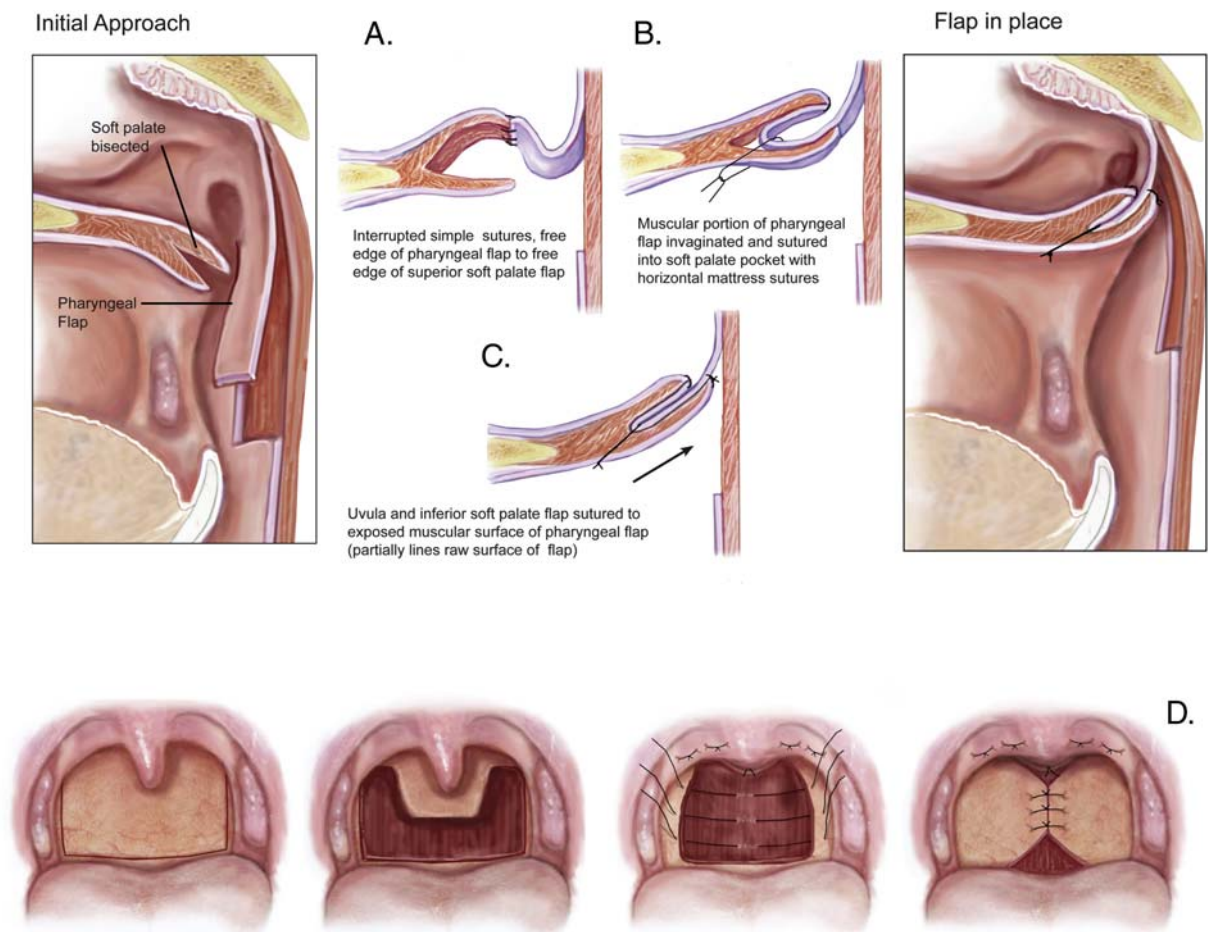


Fig. 1. Initial approach (A) to palate fishmouth incision and 3-layer inset of superior-based pharyngeal flap (B-C). Donor site can usually be closed, at least partially (D).

متن کامل مقاله

دریافت فوری ←

ISIArticles

مرجع مقالات تخصصی ایران

- ✓ امکان دانلود نسخه تمام متن مقالات انگلیسی
- ✓ امکان دانلود نسخه ترجمه شده مقالات
- ✓ پذیرش سفارش ترجمه تخصصی
- ✓ امکان جستجو در آرشیو جامعی از صدها موضوع و هزاران مقاله
- ✓ امکان دانلود رایگان ۲ صفحه اول هر مقاله
- ✓ امکان پرداخت اینترنتی با کلیه کارت های عضو شتاب
- ✓ دانلود فوری مقاله پس از پرداخت آنلاین
- ✓ پشتیبانی کامل خرید با بهره مندی از سیستم هوشمند رهگیری سفارشات