



Contents lists available at ScienceDirect

Journal of Orthopaedic Science

journal homepage: <http://www.elsevier.com/locate/jos>

Original Article

The position of the aorta relative to the spine in patients with Pott's thoracolumbar angular kyphosis

Yan Liang^a, Yongfei Zhao^b, Haiying Liu^{a, **}, Zheng Wang^{b, *}^a Peking University People's Hospital, Beijing, 100044, China^b The General Hospital of Chinese People's Liberation Army (301 Hospital), Beijing, 100853, China

ARTICLE INFO

Article history:

Received 9 August 2017

Received in revised form

26 October 2017

Accepted 2 November 2017

Available online xxx

ABSTRACT

Study design: Analyze the position of the aorta in patients with Pott's thoracolumbar angular kyphosis by computed tomography.

Objective: To investigate the anatomic position of the aorta relative to spine in patients with Pott's thoracolumbar angular kyphosis.

Summary of background data: The complication of aorta injury is rare in the procedure of spinal osteotomy for the correction of Pott's thoracolumbar angular kyphotic deformity. However, there would be a disastrous consequence once it happened. Therefore, knowing about the position of aorta relative to the spine is of great importance. From the authors' knowledge, there are no reports about the research on the position of the aorta relative to the spine in patients with Pott's thoracolumbar angular kyphosis.

Methods: Thirty patients with Pott's thoracolumbar angular kyphosis and thirty patients without spine deformity were recruited and divided into two groups. The CT images of both groups from T10 to L1 were obtained to evaluate the left pedicle-aorta angle and distance. In the patients with Pott's thoracolumbar angular kyphosis, the affected vertebral bodies were fused, so we measured the left pedicle-aorta angle and distance of the fused vertebral bodies. For the normal group, we measured the left pedicle-aorta angle and distance from T10 to L1 and got the average data, then compared with the Pott's group with independent sample *t* test. The Pearson correlation analysis was used to evaluate the association between the change of the aortic position and Konstam's angle and LL.

Results: The left pedicle-aorta angles ($-8.95 + 2.89^\circ$) in Pott's group are smaller and the distances ($6.36 + 0.77$ cm) are larger than those in normal group ($P < 0.05$). In patients with Pott's thoracolumbar angular kyphosis, with increased Konstam's angle, the left pedicle-aorta angles becomes smaller ($r = -0.495$, $P < 0.05$) and the left pedicle-aorta distances becomes larger ($r = 0.486$, $P < 0.05$). However, there is no remarkable correlation between lumbar lordosis and the left pedicle-aorta angles or distances.

Conclusion: In patients with Pott's thoracolumbar angular kyphosis, the aorta of the fused vertebrae shifts anteromedially to the vertebral body, and the aorta is relatively farther away from the vertebral body compared with the normal subjects. Therefore, the surgeon should be aware of the change of the position of the aorta to avoid the disastrous complication vessel injury.

© 2017 The Japanese Orthopaedic Association. Published by Elsevier B.V. All rights reserved.

* Corresponding author. Orthopedic Department, The General Hospital of Chinese People's Liberation Army (301 hospital), No.28, Fu Xing Rd, Hai Dian District, Beijing, 100853, China. Fax: +86 10 88219862.

** Corresponding author. Department of Spinal Surgery, Peking University People's Hospital, No.11, Xi Zhimen South Street, Xi Cheng District, Beijing, 100044, China.

E-mail addresses: liangyan7503@163.com (Y. Liang), lakezyf@hotmail.com (Y. Zhao), 393805151@qq.com (H. Liu), orth_wangzheng301@163.com (Z. Wang).

1. Introduction

Pott's deformity was first described in 1877 by Pott [1], which was characterized by forming local angular kyphosis in sagittal plane. The hazards of Pott's angular kyphosis are as follows: spinal stenosis, change of sagittal balance, paraplegia, lower of life quality and so on.

Osteotomy is an effective way to correct the deformity associated with Pott's angular kyphosis. Various techniques have been mentioned which are PSO (pedicle subtraction osteotomy),

Transpedicular eggshell osteotomy, VCR (vertebral column resection), VCD (vertebral column decancellation) [2,3]. The complication of aorta injury is rare in the procedure of spinal osteotomy for the correction of deformity. However, there would be a disastrous consequence once it happened. Some cases have been reported in the literature [4,5]. According to the reports about the aorta injury in the surgical treatment of adolescent idiopathic scoliosis, the manifestation of aorta injury is mainly bleeding and pseudoaneurysm formation [6,7]. Several studies have evaluated the position of the aorta relative to the spine in idiopathic scoliosis [8–11]. Feng [12] recently showed a migration of the aorta from a more posterolateral position before osteotomy in ankylosing spondylitis to a more anteromedial position after surgery. But no study has been published for describing the anatomic position of the aorta relative to the spine in patients with Pott's angular kyphosis. The purpose of our study is to evaluate the shift of the position of the aorta relative to spine in patients with Pott's thoracolumbar angular kyphosis. There would be important implications for the osteotomy surgical strategy.

2. Materials and methods

This retrospective study was approved by the medical ethics committee of our hospital. A total of 30 patients (13 females and 17 males) with Pott's thoracolumbar angular kyphosis and 30 patients (14 females and 16 males) without spine deformity in our hospital were recruited in this study. All subjects met the following inclusion criteria: (1) the apex of kyphosis was between T10 and L1; (2) computed tomographic (CT) scans of the lower thoracic and upper lumbar spines were available; The exclusion criteria were as follows: (1) congenital vascular abnormality; (2) previous spinal or cardiothoracic surgery; (3) coronal plane imbalance (defined as the value of trunk shift exceeds 2.0 cm); With respect to age or sex distribution, there was no significant difference between the 2 groups. Informed consents were obtained from all subjects.

2.1. Measurements

The standard standing posterior-anterior and lateral X-ray films of the whole spine were obtained to measure the Cobb angle. (1) Konstam's angle, measured according to Konstam's method. (2) The lumbar lordosis (LL), defined as the Cobb angle between the 2 lines through the inferior endplate of the L1 and superior endplate of S1, respectively.

The CT scans of the lower thoracic and lumbar spines of patients with Pott's angular kyphosis were obtained to evaluate the status of the fused vertebrae and the severity of ossification of the anterior longitudinal ligaments. The CT scans of the lower thoracic and lumbar spines of patients without spine deformity were collected. All DICOM data were transferred to a personal computer and analyzed by DICOM software (MMWP station and the affiliated Syngo software). We adopt a Cartesian coordinate system to measure the position of the aorta relative to the spine according to the Takeshita's methods [13] (Fig. 1). The middle point of the base of the left superior facet was selected as the origin of this coordinate system. A line connects the middle points of both bases of the superior facets are defined as the X-axis. The Y-axis perpendicular to the X-axis is drawn ventrally from the origin. To quantify the position of the aorta, we measure the following parameters. For patients with Pott's thoracolumbar angular kyphosis, the vertebral bodies fused, we just measured the parameters of the fused vertebral bodies. For the normal group, the parameters from T10 to L1 were measured.

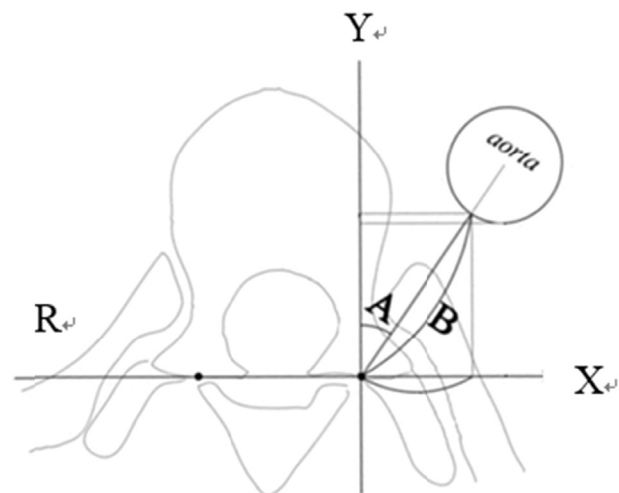


Fig. 1. Cartesian coordinate system: A: The left pedicle–aorta angle. B: The left pedicle–aorta distance.

1. The left pedicle–aorta angle: The angle formed by the Y-axis and a line connecting the origin and the center of the aorta is defined as the left pedicle–aorta angle.
2. The left pedicle–aorta distance: The distance from the edge of the aorta to the origin as the left pedicle–aorta distance.

2.2. Statistical analysis

The data were analyzed using SPSS 19.0. An independent sample *t* test was performed to determine the differences between the two groups. The Pearson Correlation Analysis was used to evaluate the association between the aortic position and Konstam's angle and LL. Significance was defined as a *P* value of less than 0.05.

3. Results

X-ray measurements: The average Konstam's angle was 80.9° (47.4°–134.7°) and the average LL was 85.5° (48.7°–132.1°).

3.1. CT measurement

3.1.1. The left pedicle–aorta angle

In normal group, the left pedicle–aorta angle gradually decreased from T10 to L1. In the Pott's group, the left pedicle–aorta angle of fusion vertebrae was $-8.95 \pm 2.89^\circ$, which is smaller than all the parameters (T10–L1, averaged) of normal group ($P < 0.05$) (Table 1). The outcome indicated that the aorta shifts anteromedially to the vertebral body in patients with Pott's thoracolumbar angular kyphosis.

3.1.2. The left pedicle–aorta distance

In normal group, the left pedicle–aorta distance gradually increased from T10 to L1. In the Pott's group, the left pedicle–aorta

Table 1

The average left pedicle–aorta angle in the fusion level of Pott's patient compared with the normal person from T10 to L1.

	Pott's group	Normal group	<i>t</i>	<i>P</i>
T10	$-8.95 \pm 2.89^\circ$	$13.95 \pm 3.99^\circ$	-25.4	0.000
T11		$8.05 \pm 4.27^\circ$	-18.1	0.000
T12		$2.41 \pm 2.85^\circ$	-15.3	0.000
L1		$-3.55 \pm 2.09^\circ$	-8.3	0.000
Average		$5.21 \pm 7.35^\circ$	-10.3	0.000

متن کامل مقاله

دریافت فوری ←

ISIArticles

مرجع مقالات تخصصی ایران

- ✓ امکان دانلود نسخه تمام متن مقالات انگلیسی
- ✓ امکان دانلود نسخه ترجمه شده مقالات
- ✓ پذیرش سفارش ترجمه تخصصی
- ✓ امکان جستجو در آرشیو جامعی از صدها موضوع و هزاران مقاله
- ✓ امکان دانلود رایگان ۲ صفحه اول هر مقاله
- ✓ امکان پرداخت اینترنتی با کلیه کارت های عضو شتاب
- ✓ دانلود فوری مقاله پس از پرداخت آنلاین
- ✓ پشتیبانی کامل خرید با بهره مندی از سیستم هوشمند رهگیری سفارشات